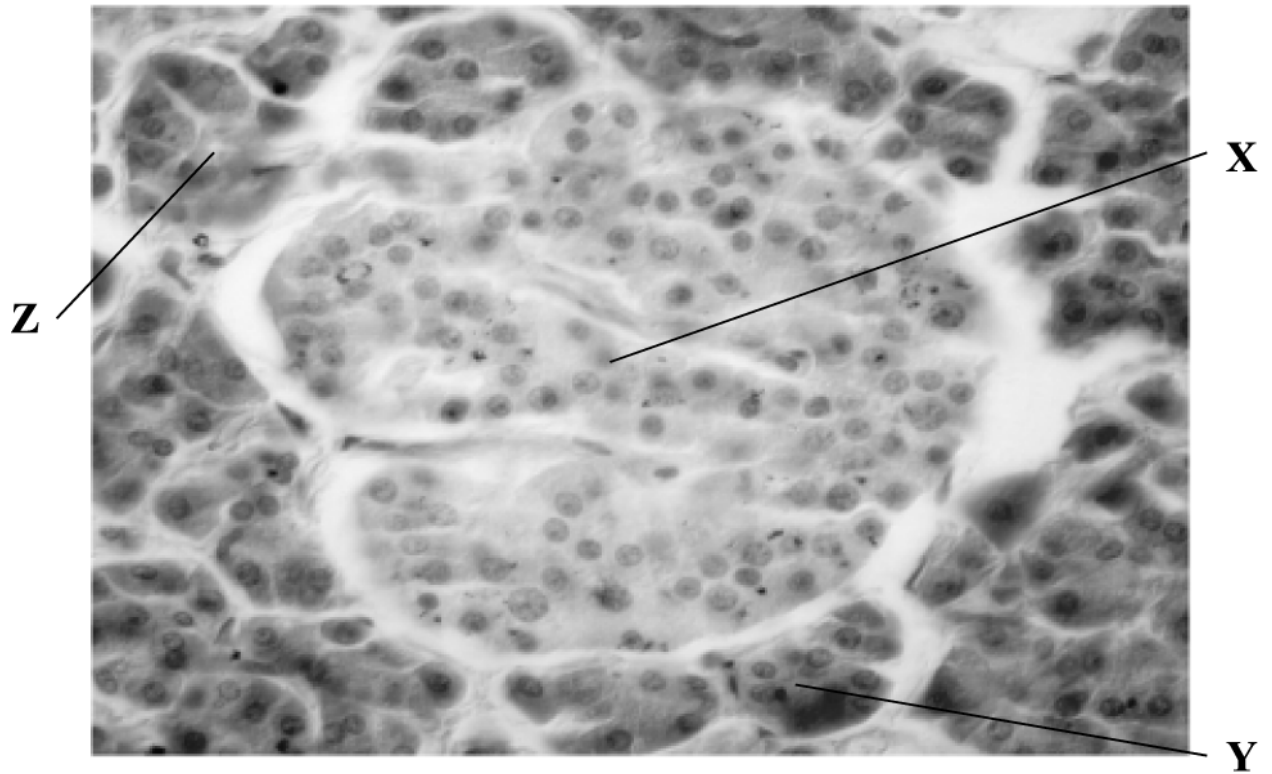


1. The image below in Fig. 25.1 shows a section of pancreatic tissue as seen under a microscope.



**Fig. 25.1**

A student identifies X as endocrine cells, Y as alpha cells and Z as Islets of Langerhans.

Is the student correct?

- A X, Y and Z are correct
- B only X and Y are correct
- C only Y and Z are correct
- D only X is correct

Your answer

[1]

2. Which of the options, A to D, is true of type 2 diabetes?

A caused by autoimmunity

B present from birth

C rapid onset

D slow onset

Your answer

[1]

**END OF QUESTION PAPER**

### Mark Scheme

Question			Answer/Indicative content	Marks	Guidance
1			D	1	
			Total	1	
2			D	1	
			Total	1	